

FEASIBILITY OF COREGISTERED OPTO-ACOUSTIC AND ULTRASONIC IMAGING FOR DIFFERENTIATION OF MALIGNANT FROM BENIGN BREAST TUMORS

Pamela Otto^{1*}, Kenneth Kist¹, N. Carol Dornbluth¹, B. Michelle McCorvey¹, Jason Zalev², Don Herzog², Bryan Clingman², Tom Miller², Remie Smith², Sergey Ermilov³, Vyacheslav Nadvoretsky³, Andre Conjusteau³, Richard Su³, Travis Hernandez³, Alexander Oraevsky^{2,3}

¹*University of Texas Health Science Center, San Antonio, Texas, USA*

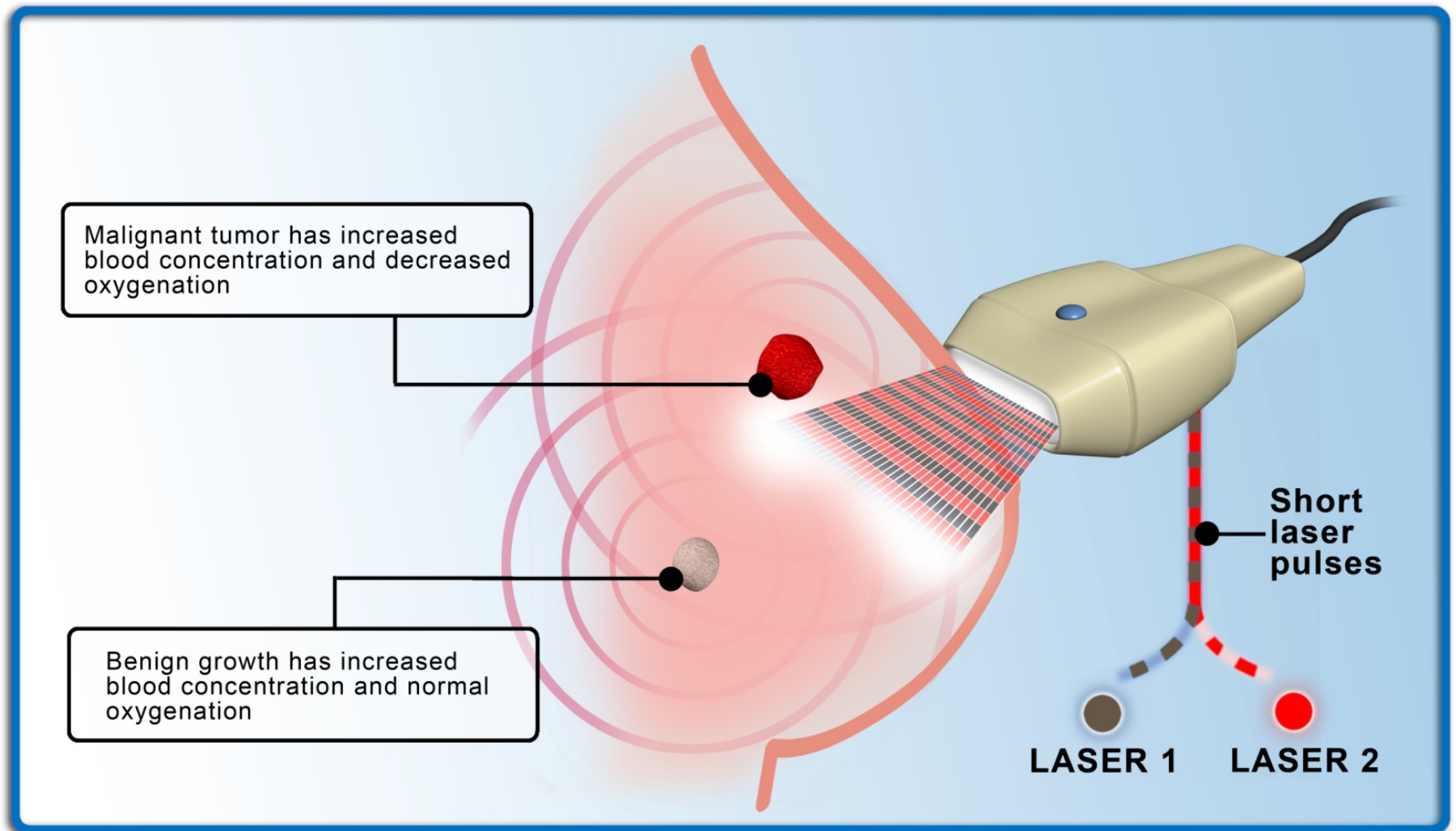
²*Seno Medical Instruments, San Antonio, Texas, USA*

³*TomoWave Laboratories, Houston, Texas, USA*

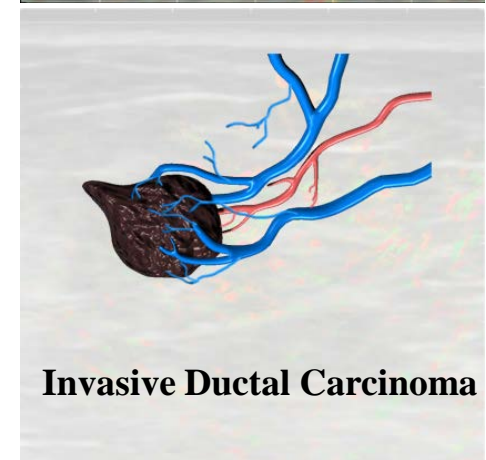
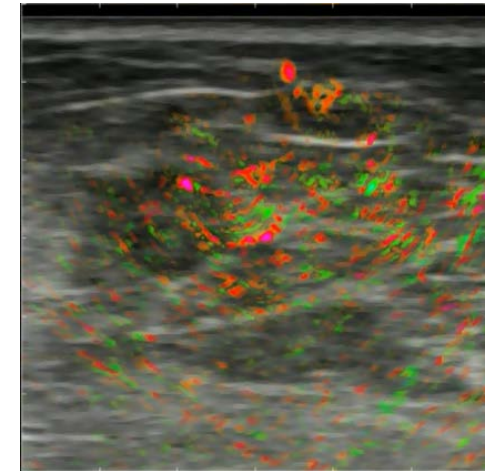
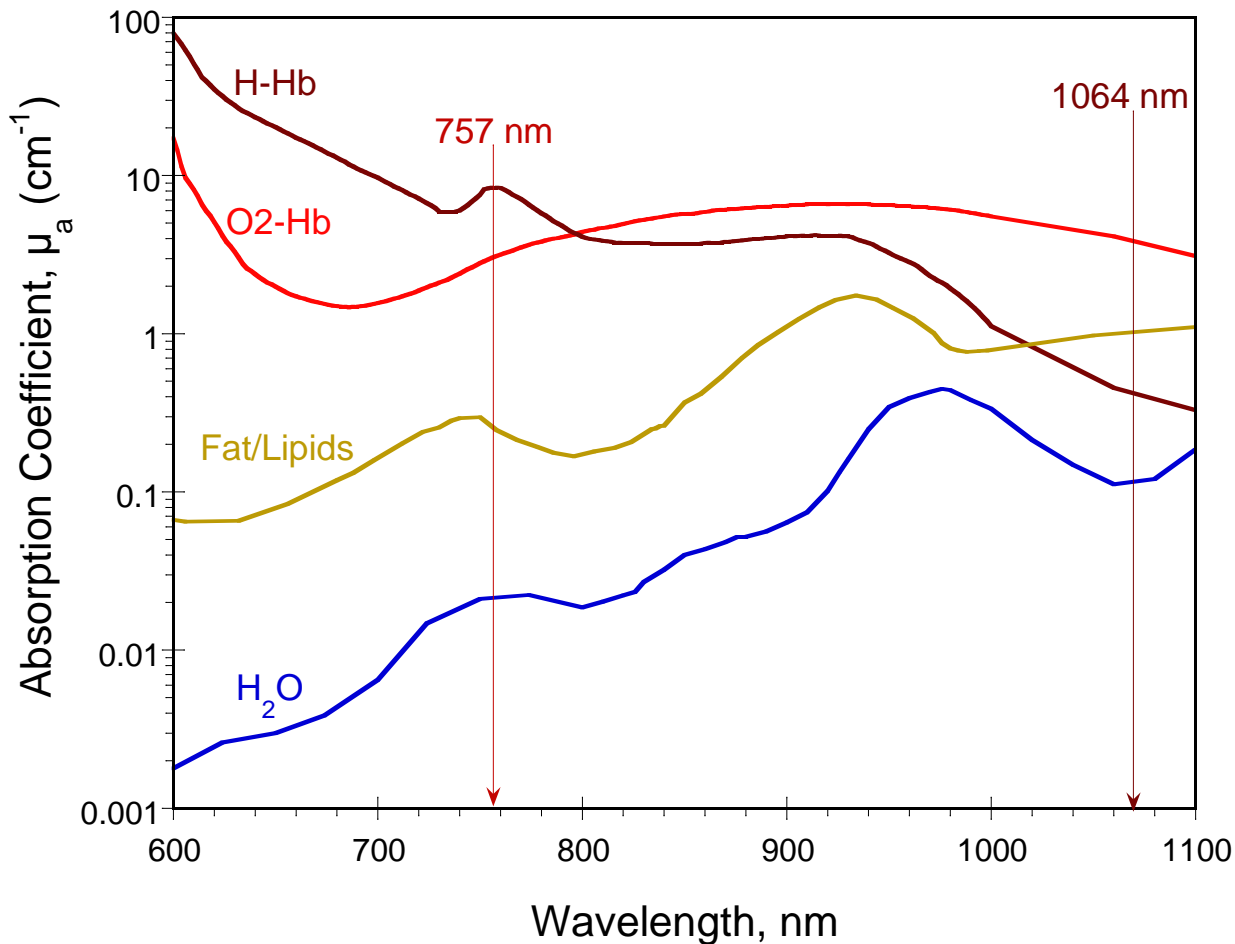


The Imagio™ System

— The Combination of OA and US —



Method of Cancer Diagnosis Based on Tumor Microvasculature

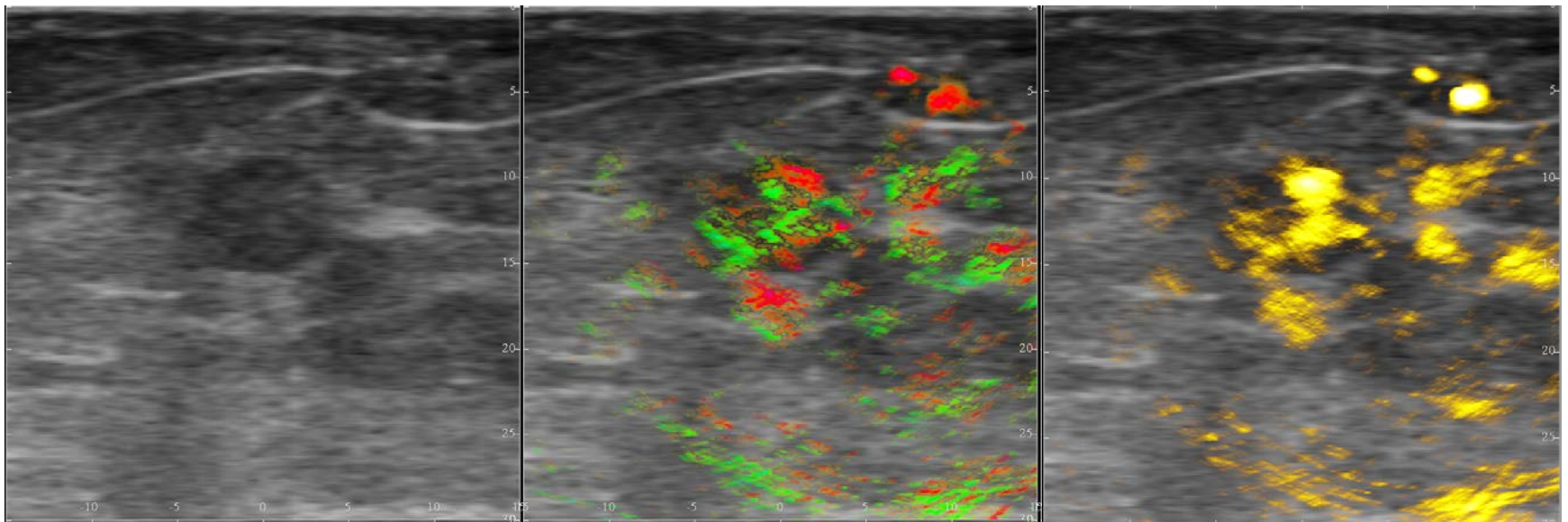


Coregistered Ultrasonic and Optoacoustic Images

Breast Morphology

Morphology + Blood [SO₂]

Morphology + [THb]



Ultrasound

Opto-Acoustic / Ultrasound

Opto-Acoustic / Ultrasound

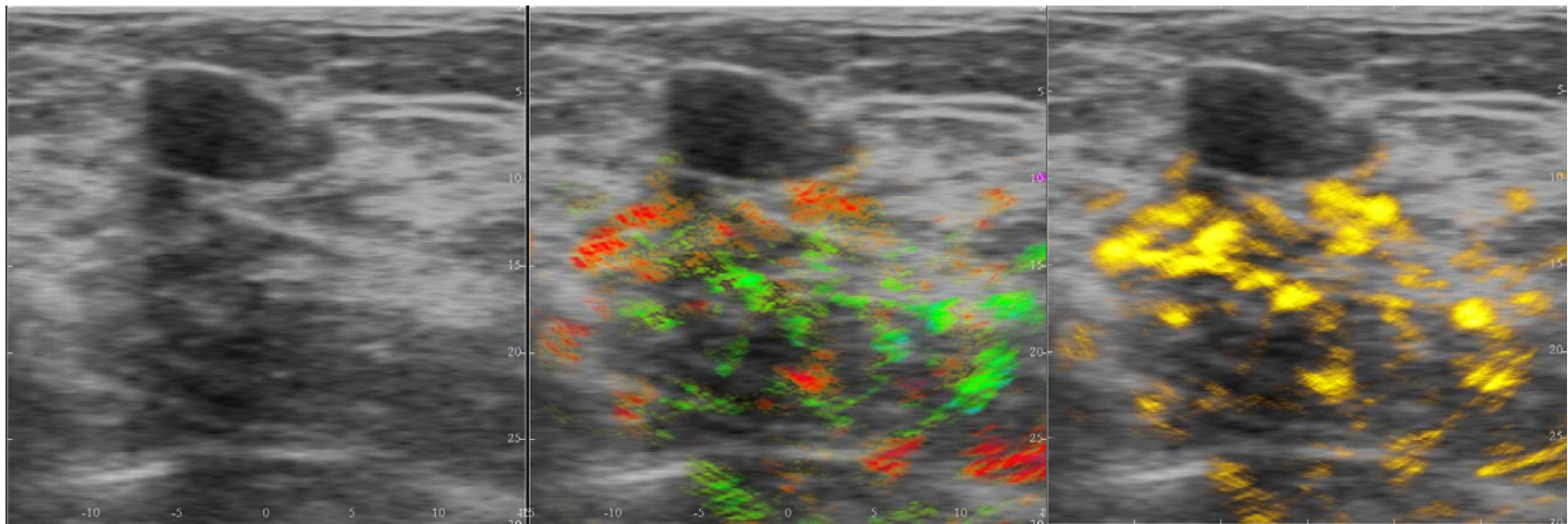
Invasive Ductal Carcinoma

Coregistered Ultrasonic and Optoacoustic Images

Breast Morphology

Morphology + Blood [SO₂]

Morphology + [THb]



Ultrasound

Opto-Acoustic / Ultrasound

Opto-Acoustic / Ultrasound

Benign Fibroadenoma

RESULTS and CONCLUSION

OA Imaging as an Emerging Technology

RESULTS

- 14 tumors identified by mammography and ultrasound as suspicious for malignancy; 7 were confirmed malignant by biopsy.
 - 6 out of 7 histologically benign tumors were differentiated as benign with opto-acoustics.
 - 6 of 7 carcinomas were correctly identified by opto-acoustics.
- Opto-acoustics correctly diagnosed 12 of the 14 lesions.***

CONCLUSION

- Opto-acoustic imaging provides additional diagnostic information based on angiogenesis and blood oxygen saturation.
- These data represent pilot 14 subjects of a 100 patient study.